

FramingHam

on ophthalmology

Intravitreal aflibercept (VEGF Trap-Eye) in wet age-related macular degeneration

Ophthalmology, 2012 December; 119(12):2537–48

The SECURE study:

long-term safety of ranibizumab 0.5 mg in neovascular age-related macular degeneration

Ophthalmology, 2013 January; 120(1):130–9

Spectral-domain optical coherence tomography of the choroid during Valsalva maneuver

American Journal of Ophthalmology, 2012 October; 154(4):687–92

Myopic maculopathy: a review

Ophthalmologica, 2012; 228(4):197–213

Visual loss after use of intraocular silicone oil associated with thinning
of inner retinal layers

Acta Ophthalmologica, 2012 December; 90(8):733–7

The *p53* codon 72 polymorphism (rs1042522)
is associated with proliferative vitreoretinopathy: the retina 4 project

Ophthalmology, 2012 December 1; Epub ahead of print

A genetic case-control study confirms the implication of *SMAD7* and *TNF locus*
in the development of proliferative vitreoretinopathy

Investigative Ophthalmology & Visual Science, 2012 December 20; Epub ahead of print

Retained subretinal perfluorocarbon liquid in microincision 23-gauge versus
traditional 20-gauge vitrectomy for retinal detachment repair

Retina, 2012 November–December; 32(10):2127–32

and more...

ISSUE 1, 2013

CURRENT TITLES

Framingham *on atherosclerosis*
 Framingham *on breast cancer*
 Framingham *on depression*
 Framingham *on dermatology*
 Framingham *on diabetes*
 Framingham *on gastroenterology*
 Framingham *on haematological malignancies*
 Framingham *on hepatitis*
 Framingham *on hypertension*
 Framingham *on infectious diseases*
 Framingham *on lung cancer*
 Framingham *on neuropathic pain*
 Framingham *on Parkinson's disease*
 Framingham *on renal cell carcinoma*
 Framingham *on thrombosis*
 Framingham *on urology*
and many more...

OUR PURPOSE

The Framingham series of publications is designed to meet clinical specialists' need for a reliable guide to the most important articles appearing in their field.

Each issue presents an authoritative selection from the recently published literature, with the emphasis on evidence-based medicine. Articles are recommended for inclusion by Framingham's editorial office and an advisory board headed by key opinion leaders in the relevant clinical area.

Framingham's team of medical writers prepares original abstracts of these articles, in a structured format that presents the main points at a glance. Our aim is to convey the essence of each article in a concise but readable style.

Issues are published every three to four months.

ADVISORY BOARD

Ângela Carneiro, MD PhD*
 Hospital São João
 Porto, Portugal

Angelina Meireles, MD*
 Porto Hospital Centre -
 Hospital Santo António
 Porto, Portugal

Nuno Gomes, MD*
 Hospital of Braga
 Braga, Portugal

Ricardo Faria, MD*
 Hospital São Teotónio
 Viseu, Portugal

Rufino Silva, MD PhD*
 University Hospital of Coimbra
 Association for Innovation and
 Biomedical Research on Light
 and Image (AIBILI)
 Coimbra, Portugal

Teresa Quintão, MD*
 Gama Pinto Ophthalmology
 Institute
 Lisbon, Portugal

*on behalf of the "Retina Study Group (GER)", Portugal

DISCLAIMER

The abstracts in this publication are prepared with care to reflect the views expressed by the author or authors of the original source material. These views are not necessarily those of the publisher. While every care is taken to avoid errors, these cannot always be avoided; readers are advised to independently validate any data and recommendations contained herein before acting on this information. The publisher disclaims any responsibility or liability for the accuracy of such information.

Framingham**Editor**

Neil Carter Abbot

Medical Writers (this issue)

Derek Collett
 Jane Grills
 Gill Gummer
 Kathy Longley
 David Newton

Art Director

Jan van Halm

Layout and Printing

Van den Berg,
 Zwijndrecht, the Netherlands

Publishing Director

Evelien Enter

Publisher

Waldemar H.G. Dobrowolski

Framingham bv

Amaliaaan 126 G
 3743 KJ Baarn
 The Netherlands
 framingham@framingham.nl

Framingham *on ophthalmology*
 is supported by an unrestricted
 educational grant from
Bayer Portugal S.A.
 Carnaxide, Portugal

© 2013 Framingham bv

COMMENTARY PAGE OPHTHALMOLOGY

By *Ângela Carneiro, MD PhD*

The new intravitreal treatments and the increasing number of indications for intravitreal use of the drugs are main topics in the literature. In this issue we have four papers concerning these topics with important results concerning the use of aflibercept, ranibizumab and bevacizumab in the treatment of wet AMD, venous occlusion and diabetic macular edema.

The first paper reports the results of VIEW 1 and VIEW2 after comparison of the safety and efficacy of ranibizumab monthly to aflibercept monthly or aflibercept every two months after 3 initial monthly injections. The trial did not compare the two drugs head to head using the same regime of treatment. However, one-year results demonstrated that aflibercept was non-inferior and clinically equivalent to ranibizumab monthly.

The results of the Secure trial, an open-label, phase IV extension study, the long-term safety of intravitreal ranibizumab in the treatment of wet AMD is evaluated in the second paper. During the 2-year extension of one-year treatment, ranibizumab administered using a VA-guided dosing regimen, was well tolerated.

The results of these studies are important not only by themselves but also because different regimens of treatment are being tested for neovascular AMD using different parameters for retreatment, maintaining good visual results, reducing the number of treatments and probably allowing less monitoring visits during the follow-up.

The paper from Brown et al. details the results of the Copernicus study. This study compares the efficacy of aflibercept with six initial monthly injections followed by aflibercept as needed to sham injections until 24 weeks followed by aflibercept as needed in the treatment of macular edema secondary to central retinal vein occlusion. The results demonstrated a great benefit of patients treated with aflibercept monthly over patients not treated at week 24.

Another main topic in literature is vitreoretinal surgery. The papers from Pastor-Idoate and Rojas et al identify the genes and polymorphisms probably associated to development of proliferative vitreoretinopathy in Europe. This issue is important for the comprehension of this significant cause of failure of retinal detachment surgery.

In another interesting paper (Garg et al) the increased incidence of retained subretinal perfluorocarbon liquid in patients undergoing 23-gauge vitrectomy compared to those undergoing 20-gauge vitrectomy is investigated. Nevertheless, the numbers presented are very similar not allowing a solid conclusion.

The new insights that spectral domain OCT can achieve in the normal physiology and pathology of choroid and retina are elucidated with the paper from Falcão et al. In this study the choroidal thickness during Valsalva maneuver is quantified. The thinning of inner retinal layers after intraocular silicone oil use is characterized and quantified in the paper from Christensen et al.

In this issue we have also a paper (Jonas et al) identifying the multiple cytokines present in high concentrations in the aqueous humor of patients with diabetic macular edema (DME). This fact confirms the multifactorial mechanisms involved in development of DME and it is the reason for the use of combination therapies for the treatment. The results of some of these combination therapies in the treatment of diffuse DME are presented in partial 24 months results of the Pan-American Collaborative Retina Study Group.

Finally a very good review article from Silva et al about pathological myopia give us an actual, detailed view of the knowledge about this theme. The new treatment options concerning CNV associated to pathological myopia are discussed and the results of case series and clinical trials available until now are presented.

INTRAVITREAL AFLIBERCEPT (VEGF TRAP-EYE) IN WET AGE-RELATED MACULAR DEGENERATION

Ophthalmology, 2012 December; 119(12):2537–48

AUTHORS: HEIER JS, BROWN DM, CHONG V, KOROBELNIK JF, KAISER PK, NGUYEN QD, KIRCHHOF B, HO A, OGURA Y, YANCOPOULOS GD, STAHL N, VITTI R, BERLINER AJ, SOO Y, ANDERESI M, GROETZBACH G, SOMMERAUER B, SANDBRINK R, SIMADER C, SCHMIDT-ERFURTH U; FOR THE VIEW 1 AND VIEW 2 STUDY GROUPS
CENTRE FOR CORRESPONDENCE: DEPARTMENT OF OPHTHALMOLOGY, MEDICAL UNIVERSITY OF VIENNA, VIENNA, AUSTRIA

BACKGROUND & AIM: Anti-vascular endothelial growth factor (VEGF) therapies, such as ranibizumab, are the mainstay of treatment for age-related macular degeneration (AMD), but are associated with a risk of serious adverse events (AEs) and entail monthly visits to a retinal specialist. Accordingly, there is a need for new therapies with improved safety. Intravitreal aflibercept injection (IAI) has a binding affinity to VEGF substantially greater than that of ranibizumab, and this may improve efficacy or result in a substantially longer duration of action that could allow less frequent dosing. The aim of this study was to compare the efficacy and safety of IAI and ranibizumab.

STUDY DESIGN: Two double-masked, multicentre, randomized clinical trials (VIEW 1 and 2).

ENDPOINTS: The primary endpoint was non-inferiority (margin of 10%) of aflibercept to ranibizumab in the proportion of patients maintaining vision at week 52.

METHOD: Patients ($n=2419$) with active, subfoveal, choroidal neovascularization lesions (or juxtafoveal lesions with leakage affecting the fovea) secondary to AMD were randomized to receive either IAI 0.5 mg monthly (0.5q4), 2.0 mg monthly (2q4) or 2.0 mg every 2 months after three initial

monthly doses (2q8) or ranibizumab 0.5 mg monthly (Rq4). Maintenance of vision was defined as loss of <15 letters on the best-corrected visual acuity (BCVA) score.

RESULTS: All the aflibercept groups were non-inferior and clinically equivalent to monthly ranibizumab with regard to maintenance of vision. The proportion of patients maintaining vision was 95.1%, 95.9%, 95.1% and 94.4% for 2q4, 0.5q4, 2q8 and Rq4, respectively, in VIEW 1, and 95.6%, 96.3%, 95.6% and 94.4%, respectively, in VIEW 2. All aflibercept regimens were within 0.5 letters of Rq4 for mean change in BCVA. Similar improvements in anatomic measures were observed for all aflibercept regimens. IAI was generally well tolerated; the rate of ocular injection-related treatment-emergent serious adverse events per 1000 injections was 1.1, 0.8, 0.1 and 0.2 for Rq4, 2q4, 0.5q4 and 2q8, respectively. Similar overall incidences of systemic adverse events (which included eye disorders, endophthalmitis, procedural complications and increased intraocular pressure) were observed for IAI and ranibizumab.

CONCLUSION: Intravitreal aflibercept injection (dosed monthly or every 2 months after 3 initial monthly doses) resulted in similar visual or anatomic outcomes and safety to ranibizumab dosed monthly.

INTRAVITREAL AFLIBERCEPT INJECTION FOR MACULAR EDEMA SECONDARY TO CENTRAL RETINAL VEIN OCCLUSION: 1-YEAR RESULTS FROM THE PHASE 3 COPERNICUS STUDY

American Journal of Ophthalmology, 2013 March; 155(3):429–37

AUTHORS: BROWN DM, HEIER JS, CLARK WL, BOYER DS, VITTI R, BERLINER AJ, ZEITZ O, SANDBRINK R, ZHU X, HALLER JA

CENTRE FOR CORRESPONDENCE: WILLS EYE INSTITUTE, PHILADELPHIA, PENNSYLVANIA, USA

BACKGROUND & AIM: Anti-vascular endothelial growth factor (VEGF) therapies have transformed the treatment of patients with macular oedema secondary to central retinal venous occlusion (CRVO). In the COPERNICUS study, patients with this condition who had received intravitreal aflibercept injections (IAI) experienced improved visual acuity (VA) and reduced ocular adverse events after 24 weeks compared with patients receiving sham injections. The aim of this analysis was to evaluate the efficacy and safety of IAI to week 52 of this study, after the sham group had received a different dosing regimen from week 24 onwards.

STUDY DESIGN: Phase III, randomized clinical trial.

ENDPOINT: Proportion of patients with a change in best-corrected visual acuity

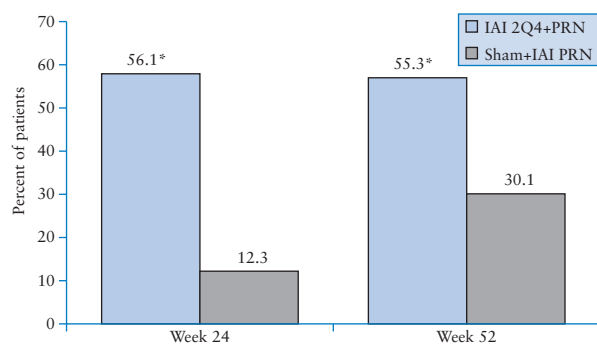
(BCVA) score of ≥ 15 letters from baseline to weeks 24 and 52.

METHOD: Patients (one eye each) with macular oedema secondary to CRVO were randomized to receive either 6 monthly injections of 2 mg IAI (IAI 2Q4; $n=115$) or sham injections ($n=74$). Between weeks 24 and 52, all patients received 2 mg IAI as needed (IAI 2Q4+PRN and sham+IAI PRN, respectively) according to retreatment criteria.

RESULTS: At week 24, a significantly greater proportion of IAI 2Q4 patients than sham patients had gained ≥ 15 letters from baseline ($p<0.001$), and IAI 2Q4+PRN continued to be superior at week 52 (Figure). At week 24, the mean change from baseline was 17.3 and -4.0 letters in the IAI 2Q4+PRN and sham groups, respectively ($p<0.001$). At week 52, the mean gain of letters was 16.2 and 3.8 in the IAI 2Q4+PRN and sham+IAI PRN groups, respectively ($p<0.001$). The mean number of injections was 3.9 and 2.7 in the sham+IAI PRN and IAI 2Q4+PRN groups, respectively. Similar proportions of patients in each group had experienced at least one ocular treatment-emergent adverse event by week 52.

CONCLUSION: After intravitreal aflibercept injection, the improvements in VA observed at week 24 were largely maintained to week 52 in patients with macular oedema attributable to CRVO.

Proportion of patients with BCVA improvement ≥ 15 letters at weeks 24 and 52



* = $p<0.001$ compared with sham group

THE SECURE STUDY: LONG-TERM SAFETY OF RANIBIZUMAB 0.5 MG IN NEOVASCULAR AGE-RELATED MACULAR DEGENERATION

Ophthalmology, 2013 January; 120(1):130–9

AUTHORS: SILVA R, AXER-SIEGEL R, ELDEM B, GUYMER R, KIRCHHOF B, PAPP A, SERES A, GEKKIEVA M, NIEWEG A, PILZ S; FOR THE SECURE STUDY GROUP
CENTRE FOR CORRESPONDENCE: DEPARTMENT OF OPHTHALMOLOGY, COIMBRA UNIVERSITY HOSPITAL, COIMBRA, PORTUGAL

BACKGROUND & AIM: Vascular endothelial growth factor (VEGF) blockade with intravitreal injections of ranibizumab can improve visual acuity in patients with neovascular age-related macular degeneration (nAMD). The aim of the SECURE study was to assess the long-term safety and efficacy of intravitreal ranibizumab in patients with nAMD who had previously completed one year of ranibizumab treatment.

STUDY DESIGN: Prospective, open-label, phase IV extension study.

ENDPOINTS: Incidence and severity of ocular and non-ocular adverse events (AEs) and serious AEs; mean change in best-corrected visual acuity (BCVA) from baseline; and number of ranibizumab injections over 24 months.

METHOD: Eligible patients had subfoveal choroidal neovascularization secondary to nAMD, and had previously participated in either the EXCITE study or the SUSTAIN study. BCVA was measured monthly to determine the need for retreatment with ranibizumab. At the discretion of the investigator, intravitreal ranibizumab 0.5 mg was administered in accordance with the European product license when a patient's BCVA deteriorated by >5 letters on an Early Treatment Diabetic Retinopathy Study-like chart compared with their highest visual acuity (VA) score either in SECURE or their

previous study, and when the deterioration was attributable to nAMD.

RESULTS: A total of 234 patients were enrolled, and 210 completed the study. Patients received a mean of 6.1 ranibizumab injections over 24 months. Overall, 42% of patients had at least 7 visits at which ranibizumab was not administered, despite a VA loss of more than 5 letters, suggesting either under-treatment or that factors other than loss of VA influenced retreatment decisions. At month 24, the mean BCVA had decreased by 4.3 letters from the SECURE baseline. The most common ocular AEs were retinal hemorrhage (12.8%; 1 event related to ranibizumab), aggravated cataract (11.5%; 1 event related to ranibizumab), and increased intraocular pressure (6.4%; 1 event related to ranibizumab). Overall, serious ocular AEs of the study eye were reported in 11 patients (4.7%), including 2 patients (0.9%) with endophthalmitis considered due to ranibizumab and/or its injection. The main non-ocular AEs were hypertension (9.0%), nasopharyngitis (9.0%) and arterial thromboembolic events (5.6%).

CONCLUSIONS: Ranibizumab administered using a VA-guided dosing regimen was well tolerated during a 2-year extension of one-year treatment. No new ocular or non-ocular safety concerns were identified during long-term use of ranibizumab in nAMD.

SPECTRAL-DOMAIN OPTICAL COHERENCE TOMOGRAPHY OF THE CHOROID DURING VALSALVA MANEUVER

American Journal of Ophthalmology, 2012 October; 154(4):687–92

AUTHORS: FALCÃO M, VIEIRA M, BRITO P, ROCHA-SOUSA A, BRANDÃO EM, FALCÃO-REIS FM

CENTRES: DEPARTMENT OF OPHTHALMOLOGY, HOSPITAL DE SÃO JOÃO; FACULTY OF MEDICINE, UNIVERSITY OF PORTO, PORTO, PORTUGAL

BACKGROUND & AIM: The Valsalva manoeuvre is defined as a forced exhalation against a closed glottis, and has been associated with visual field loss in individuals who repeatedly perform it, such as musicians who play wind instruments. The manoeuvre causes an increase in intrathoracic venous pressure which is ultimately transmitted to the choroid, where it may result in vascular engorgement, increased choroidal volume and an increase in intraocular pressure. The aim of this study was to investigate the mechanisms of this phenomenon by measuring the effect of the Valsalva manoeuvre on choroidal thickness at the posterior pole.

STUDY DESIGN: Prospective, interventional case series.

ENDPOINT: Choroidal thickness.

METHOD: The study included 9 healthy volunteers (aged 25 to 38 years) without myopia greater than 6.0 diopters. Ocular pathology was also excluded by conducting

a full ophthalmic examination. Macular spectral-domain optical coherence tomography was performed in all participants using enhanced-depth imaging to obtain horizontal and vertical B-scans centred on the fovea. Scans were carried out at rest and during a Valsalva manoeuvre, which consisted of the volunteer blowing forcefully against his or her hand while occluding the nose with the index finger and thumb. Choroidal thickness was measured in each eye before and after the manoeuvre, using both horizontal and vertical scans, and using manual and semi-automatic methods.

RESULTS: The Valsalva manoeuvre had no significant effects on macular choroidal thickness. Using the semi-automatic method of assessing choroidal thickness, there were non-significant changes in subfoveal thickness (Table) of $-4.1 \mu\text{m}$ on horizontal scans ($p=0.28$) and $1.4 \mu\text{m}$ on vertical scans ($p=0.75$). The Table also shows that there were non-significant changes in mean choroidal thickness in the central $3000 \mu\text{m}$ of $8.5 \mu\text{m}$ on horizontal scans ($p=0.73$) and $-5.3 \mu\text{m}$ on vertical scans ($p=0.41$). These effects were highly reproducible, and there was a good inter-test correlation between the manual and semi-automatic measurements.

CONCLUSION: The increase in ocular pressure occurring after Valsalva manoeuvre is not due to an increase in choroidal thickness.

Choroidal thickness measurements at rest and during Valsalva manoeuvre

	Choroidal thickness (μm); mean \pm SD	
	Horizontal	Vertical
Semi-automatic subfoveal		
Rest	323.9 \pm 121.4	334.3 \pm 129.3
Valsalva	319.8 \pm 113.9	335.7 \pm 137.3
Manual subfoveal		
Rest	312.9 \pm 123.1	329.1 \pm 116.7
Valsalva	307.2 \pm 120.2	324.8 \pm 114.2
Mean choroidal thickness (central $3000 \mu\text{m}$)		
Rest	301.2 \pm 115.2	323.1 \pm 114.4
Valsalva	292.7 \pm 111.8	328.4 \pm 106.4

MYOPIC MACULOPATHY: A REVIEW

Ophthalmologica, 2012; 228(4):197–213

AUTHOR: SILVA R

CENTRE: FACULTY OF MEDICINE, UNIVERSITY OF COIMBRA, DEPARTMENT OF OPHTHALMOLOGY, COIMBRA
UNIVERSITY HOSPITAL, ASSOCIATION FOR INNOVATION AND BIOMEDICAL RESEARCH ON LIGHT AND IMAGE, COIMBRA,
PORTUGAL

BACKGROUND & AIM: High myopia is a common cause of vision loss, particularly among the young, and visual outcomes are generally poor if left untreated. The reduction in visual acuity is associated with choroidal neovascularization (CNV) and progressive atrophy in the macula, and anti-angiogenic drugs have shown promise in the treatment of myopic CNV. The aim of this article was to review the clinical findings and treatment of myopic maculopathy.

ARTICLE TYPE: Review.

FINDINGS: Pathological myopia is defined as the combination of an axial length of at least 25.5 mm, a refractive error of at least -5 dpt, and accompanying pathological changes which can include tessellated fundus, lacquer cracks, diffuse or patchy atrophy, CNV, and macular atrophy. Myopic maculopathy tends to progress along this spectrum of changes, and this is associated with the decline in visual acuity. In particular, CNV is associated with a severe reduction in corrected vision. One Australian study reported a 1.2% prevalence of myopic retinopathy in a population aged 49 years and older, though prevalence appears to vary between different ethnic groups.

The incidence of CNV in eyes with pathological myopia has been reported as 5.2%, and the risk is higher in those with lacquer cracks or patchy atrophy close to

the fovea. Other risk factors include older age, choroidal filling delay and reduced choroidal thickness. The natural course can be variable; in many cases, visual acuity may remain stable, but several studies have reported a final visual acuity of 20/200 or worse in more than half of eyes studied after 2 or more years, while younger patients appear to have better outcomes. A number of potential treatments for myopic CNV have been studied. The use of laser photocoagulation, transpupillary thermotherapy and surgical approaches are not well supported by the available evidence, while treatment with photodynamic therapy plus verteporfin appears to have a favourable outcome initially, which is not always maintained in the long term. Anti-angiogenic drugs have shown favourable results: prospective and retrospective studies have reported the benefits of bevacizumab in foveal myopic CNV (although its long-term efficacy is not yet known), while ranibizumab has shown efficacy in both juxtafoveal and subfoveal myopic CNV, potentially maintained for up to 3 years.

CONCLUSIONS: Anti-angiogenic drugs currently appear to be the most promising treatment for myopic CNV, although trials are still ongoing, and developments from age-related macular degeneration research may also be of value.

VISUAL LOSS AFTER USE OF INTRAOCULAR SILICONE OIL ASSOCIATED WITH THINNING OF INNER RETINAL LAYERS

Acta Ophthalmologica, 2012 December; 90(8):733–7

AUTHORS: CHRISTENSEN UC, LA COUR M

CENTRES: DEPARTMENT OF OPHTHALMOLOGY, GLOSTRUP HOSPITAL, UNIVERSITY OF COPENHAGEN, DENMARK

BACKGROUND & AIM: Silicone oil (SiO) is widely used as intravitreal tamponade during the repair of complex retinal detachments or giant retinal tear. Mild loss of visual acuity may develop gradually after SiO removal, but severe visual loss after the use of SiO has also been reported, though the causes of this remain unclear. The aim of this study was to investigate the incidence and possible cause of severe vision loss following use and removal of intraocular SiO in patients who had undergone uncomplicated vitrectomy and SiO injection for primary rhegmatogenous retinal detachment (RDD).

STUDY DESIGN: Retrospective, comparative case series.

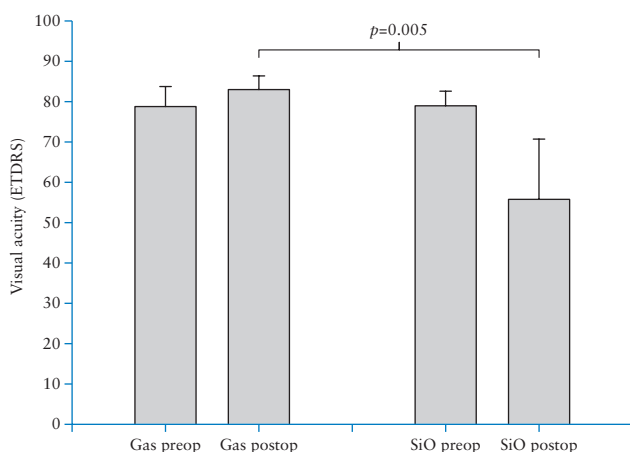
ENDPOINTS: Best-corrected visual acuity (BCVA), and high-definition optical coherence tomography parameters.

METHOD: Consecutive patients who underwent vitrectomy for primary RRD repair between 2004 and 2005 were identified. SiO (5500 centiStoke) was used as intravitreal tamponade in 162 eyes and perfluoropropane (C₃F₈) gas was used in 54 eyes. Chart review identified 16 eyes in 16 patients (9 eyes treated with SiO, 7 eyes treated with gas) with macula-on and documented visual acuity of at least 6/12 before surgery, in which SiO had been removed, cataract surgery performed and no retinal re-detachment had occurred.

RESULTS: Despite similar preoperative characteristics, postoperative BCVA was significantly worse in eyes in which SiO was used (>6/24) compared with eyes in which gas was used (>6/7.5, $p=0.005$; Figure). Overall, 3 of the 9 SiO eyes (33%) had a severe reduction in final BCVA to 6/60 or lower, and 67% had a final BCVA of 6/12 or lower. No eyes treated with gas had a final BCVA less than 6/9. Coherence tomography indicated significant thinning of the inner retinal layers of the macula in SiO-operated eyes (mean 5148 pixels) compared to eyes in which gas was used (6897 pixels; $p<0.002$).

CONCLUSION: Severe visual loss occurred in one third of patients who had RRD repair involving silicone oil, despite a good preoperative visual prognosis.

Preoperative and postoperative BCVA in eyes treated with gas or SiO tamponade



THE *P53* CODON 72 POLYMORPHISM (rs1042522) IS ASSOCIATED WITH PROLIFERATIVE VITREORETINOPATHY: THE RETINA 4 PROJECT

Ophthalmology, 2012 December 1; Epub ahead of print

AUTHORS: PASTOR-IDOATE S, RODRIGUEZ-HERNÁNDEZ I, ROJAS J, FERNÁNDEZ I, GARCÍA-GUTIERREZ MT, RUIZ-MORENO JM, ROCHA-SOUSA A, RAMKISSOON Y, HARSUM S, MACLAREN RE, CHARTERIS D, VAN MEURS J, GONZÁLEZ-SARMIENTO R, PASTOR JC; FOR THE GENETICS ON PVR STUDY GROUP
CENTRE FOR CORRESPONDENCE: DEPARTMENT OF OPHTHALMOLOGY, UNIVERSITY HOSPITAL OF VALLADOLID; AND CAMPUS MIGUEL DELIBES, VALLADOLID, SPAIN

BACKGROUND & AIM: Proliferative vitreoretinopathy (PVR) is an important cause of failure after retinal detachment surgery, leading to repeat procedures and poor anatomical and functional outcomes. As clinical risk factors for PVR do not completely account for its development, previous work has explored the role of genetic polymorphisms. The tumour suppressor gene *p53* is important in cell repair, apoptosis, immunity and inflammation, and the *p53* codon 72 polymorphism has been related to a poor functional prognosis in stroke patients. The aim of this study was to investigate the association of this polymorphism with PVR in patients undergoing primary retinal detachment surgery.

STUDY DESIGN: Case-controlled gene association study.

ENDPOINT: Association of PVR with the distribution of *p53* codon 72 polymorphism.

METHOD: The study included 550 patients who underwent surgery for primary rhegmatogenous retinal detachment, of whom 134 developed PVR, while 416 had not developed PVR grade C1 or higher after 3 months of follow-up. DNA samples were obtained from all participants, and genotyped for the codon 72 polymorphism of *p53* (rs1042522) using allele-specific primer

polymerase chain reaction. In the first phase of analysis, samples from Spain and Portugal were analysed with regard to the proportions of genotypes and proline (Pro-P) homozygote groups. In the second phase, samples from the UK and the Netherlands were analysed, following which genotypic and allelic frequencies were compared between patients with and without PVR across the whole cohort.

RESULTS: There was a significant difference in *p53* genotype frequencies at codon 72 between patients with and those without PVR in the first phase of the analysis ($p < 0.05$), but not in the second phase. The Pro homozygote was associated with an increased odds of PVR in Spain and Portugal together (odds ratio 8.12, 95% confidence interval 3.72–17.69, $p < 0.05$), but not in the UK and Netherlands together (OR 2.12, 95% CI 0.96–4.68, $p = 0.07$). The frequency of Pro homozygote carriers was higher in PVR cases than in controls, respectively, in Spain (35.6 versus 6.25), Portugal (20 versus 3.77) and the Netherlands (24.1 versus 9.8), but not in the UK (12.9 versus 9.4).

CONCLUSION: The Pro variant of the *p53* codon 72 polymorphism was associated with an increased risk of the development of PVR after primary retinal detachment surgery.

A GENETIC CASE-CONTROL STUDY CONFIRMS THE IMPLICATION OF *SMAD7* AND *TNF* LOCUS IN THE DEVELOPMENT OF PROLIFERATIVE VITREORETINOPATHY

Investigative Ophthalmology & Visual Science, 2012 December 20; Epub ahead of print

AUTHORS: ROJAS J, FERNANDEZ I, PASTOR JC, ET AL.; FOR THE GENETICS ON PVR STUDY GROUP
CENTRE FOR CORRESPONDENCE: CAMPUS UNIVERSITARIO MIGUEL DELIBES, EDIFICIO IOBA, VALLADOLID, SPAIN

BACKGROUND & AIM: The major cause of failure of retinal detachment surgery remains proliferative vitreoretinopathy (PVR). The pathogenesis of this complication is not completely understood, but inflammation is believed to have an important role. Some clinical characteristics have been found to be associated with the risk of developing PVR after surgery, but, as patients with prompt and initially successful surgery also develop PVR, genetic susceptibility needs to be explored. The aim of this study was to determine the genetic contribution to PVR in patients undergoing retinal detachment surgery.

STUDY DESIGN: Genetic case-control study.

ENDPOINT: Genes associated with PVR.

METHOD: A total of 450 Spanish patients (138 cases and 312 controls) were included in the discovery phase conducted in 2006, and 546 patients (151 cases and 395 controls) from 17 European centres were included in the replication phase conducted between 2009 and 2010. All patients had undergone primary rhegmatogenous retinal detachment surgery and were classified as controls if they did not develop PVR after 3 months of follow-up. In the discovery phase, single nucleotide polymorphisms (SNPs) from 30 candidate genes known to be involved in inflammation were

investigated, and genes significantly associated with PVR were genotyped in the replication phase. Both single and haplotypic SNP associations were analysed using stringent statistical analysis, and the Rosenberg two-stage method was used to correct for single and multiple analyses.

RESULTS: In the discovery phase, 22 single significant associations were observed in 15 genes, and significant haplotypic and sub-haplotypic associations were detected in 13 genes in multiple analyses. However, taking into account the total amount of genes, following the second stage of the Rosenberg method, 4 genes maintained a significant association with PVR after correction for multiple comparisons: *SMAD7* ($p=0.004$), *PIK3CG* ($p=0.009$), *TNF* locus ($p=0.0005$), and *TNFR2* ($p=0.019$). In the replication phase, no haplotype was associated with PVR in multiple analyses. After correction for multiple comparisons, *SMAD7* ($p=0.047$) and the *TNF* locus ($p=0.044$) remained significantly associated with PVR.

CONCLUSION: The results suggested that two genes, *SMAD7* and the *TNF* locus, were associated with the development of PVR in European patients undergoing primary rhegmatogenous retinal detachment surgery, and could provide potential new therapeutic targets for the treatment or prevention of PVR.

CYTOKINE CONCENTRATION IN AQUEOUS HUMOR OF EYES WITH DIABETIC MACULAR EDEMA

Retina, 2012 November–December; 32(10):2150–7

AUTHORS: JONAS JB, JONAS RA, NEUMAIER M, FINDEISEN P

CENTRES: DEPARTMENT OF OPHTHALMOLOGY; INSTITUTE FOR CLINICAL CHEMISTRY, MEDICAL FACULTY MANNHEIM OF THE RUPRECHT-KARLS-UNIVERSITY; DIETRICH-BONHOEFFER-GYMNASIUM WEINHEIM, HEIDELBERG, GERMANY

BACKGROUND & AIM: Diabetic retinopathy and exudative age-related macular degeneration are associated with elevated concentrations of vascular endothelium growth factor (VEGF). Other cytokines have also been found to be present at elevated levels in the eyes of patients with neovascular disorders, including monocyte chemoattractant protein (MCP)-1, intercellular adhesion molecule-1 (ICAM-1) and vascular cell adhesion molecule-1 (VCAM-1), and may provide targets for the development of new treatment strategies for these conditions. The aim of this study was to identify substances that may be present in elevated concentrations in the aqueous humour of patients with diabetic retinopathy.

STUDY DESIGN: Interventional, clinical comparative study.

ENDPOINTS: Cytokine concentrations and any association with macular thickness.

METHOD: Cytokine concentrations were measured in aqueous humour samples taken from 23 patients with diffuse diabetic macular oedema who received an intravitreal injection of triamcinolone and 22 controls undergoing age-related cataract surgery. Associations between cytokine concentrations and macular thickness were determined using Spearman correlation and multivariate analyses.

RESULTS: Significantly higher concentrations of a number of cytokines were found in the aqueous humour of patients with diffuse diabetic macular oedema than in controls. Mean retinal macular thickness was $623 \pm 170 \mu\text{m}$ in the diabetic patients. Significant ($p \leq 0.03$) correlations with retinal macula thickness were identified for epidermal growth factor, ICAM-1, interleukins (IL)-3, -6 and -8, MCP-1, monokine induced by interferon gamma, matrix metalloproteinase 9, placenta growth factor, tissue growth factor β , VCAM-1 and VEGF (Table). However, under multivariate analysis, only the concentration of ICAM-1 remained associated with macular thickness ($r=0.30$, $p=0.03$).

CONCLUSION: Numerous cytokines were found to be associated with the presence and extent of diabetic macular oedema in patients with diabetic retinopathy. Of these, ICAM-1 exhibited the greatest association with macular thickness.

Cytokines significantly associated with macular thickness, with correlation co-efficients

Cytokine	Spearman's ρ	p -value
Epidermal growth factor	0.45	0.005
ICAM-1	0.65	<0.001
IL-3	0.48	0.002
IL-6	0.47	0.003
IL-8	0.71	<0.001
MCP-1	0.53	0.001
Monokine induced by interferon gamma	0.57	<0.001
Matrix metalloproteinase 9	0.61	<0.001
Placenta growth factor	0.46	0.004
Tissue growth factor β	0.42	0.01
VCAM-1	0.44	0.006
VEGF	0.42	0.01

INTRAVITREAL BEVACIZUMAB PLUS GRID LASER PHOTOCOAGULATION OR INTRAVITREAL BEVACIZUMAB OR GRID LASER PHOTOCOAGULATION FOR DIFFUSE DIABETIC MACULAR EDEMA: RESULTS OF THE PAN-AMERICAN COLLABORATIVE RETINA STUDY GROUP AT 24 MONTHS

Retina, 2013 February; 33(2):403–13

AUTHORS: AREVALO JF, LASAVE AF, WU L, DIAZ-LLOPIS M, GALLEGO-PINAZO R, ALEZZANDRINI AA, BERROCAL MH; FOR THE PAN-AMERICAN COLLABORATIVE RETINA STUDY GROUP (PACORES)
CENTRE FOR CORRESPONDENCE: VITREORETINAL DIVISION, KING KHALED EYE SPECIALIST HOSPITAL, RIYADH, SAUDI ARABIA

BACKGROUND & AIM: Laser photocoagulation reduces visual loss in patients with diabetic macular oedema (DME) but it may be less effective in eyes with diffuse rather than centre-involved DME. Blockage of vascular endothelial growth factor (VEGF) signaling with agents such as bevacizumab represents an alternative treatment strategy. The two treatment modalities impact DME via different pathways and a combination approach may therefore be beneficial. The aim of this study was to evaluate anatomical and functional outcomes in patients with diffuse DME treated with intravitreal bevacizumab (IVB) plus grid laser photocoagulation (GLP) or either IVB or GLP alone at the end of 24 months.

STUDY DESIGN: Retrospective, comparative multicentre study.

ENDPOINT: Main outcome measures included the change in best-corrected visual acuity (BCVA) and central macular thickness at 24 months.

METHOD: Records from 318 consecutive patients (418 eyes) with diffuse DME were reviewed. Three treatment groups were identified; group A comprised a total of 141 eyes from 120 patients who received treatment with IVB, either 1.25 or 2.5 mg, alone; group B comprised 120 eyes from 94

patients who had GLP alone; and group C contained 157 eyes from 104 patients who received a combination of IVB plus GLP treatment. All patients had baseline ophthalmic assessments including BCVA using Early Treatment of Diabetic Retinopathy Study charts, and follow-up data was available for all eyes for 24 months. BCVA was assessed one month after initial treatment and monthly thereafter.

RESULTS: An improvement in BCVA scores from baseline to 24 months was observed in all three treatment groups ($p < 0.0001$). The improvement in BCVA in group A was significantly better than in group B ($p = 0.013$), but the improvement rate was not significantly different between groups A and C ($p = 0.167$) or between groups B and C ($p = 0.092$). A decrease in central macular thickness was observed in all groups from baseline to the 24-month follow-up ($p < 0.0001$). The between-group comparison revealed a greater reduction in central macular thickness in group A than either group B or C ($p < 0.001$).

CONCLUSIONS: Treatment of diffuse diabetic macular oedema with IVB, with or without GLP, improved visual acuity at 24 months. IVB without GLP appeared to be superior to GLP alone in improving or stabilizing BCVA in these patients.

... ..





NOVO tratamento para a DMI^a exsudativa UMA ADMINISTRAÇÃO A CADA 2 MESES^{b1} A VIDA PARA ALÉM DAS LETRAS



EYLEA[®] melhora e mantém a visão com uma administração a cada 2 meses^b, sem necessidade de monitorização entre injeções^{1,2}

Os estudos VIEW demonstraram que EYLEA[®] é um tratamento eficaz para a DMI^a exsudativa, com o potencial de redução do risco associado às injeções intravítreas mensais e ao “peso” da monitorização mensal²

^a DMI - Degenerescência Macular relacionada com a Idade neovascular (húmida)

^b Após uma injeção por mês durante 3 doses consecutivas

Referências: 1. Resumo das Características do Medicamento EYLEA[®]. 2. Heier JS, et al. Intravitreal Aflibercept (VEGF Trap-Eye) in Wet Age-Related Macular Degeneration. *Ophthalmology* 2012; 119: 2537-2548

Medicamento sujeito a receita médica restrita a certos meios especializados.

Para mais informações deverá contactar o titular de AIM
BAYER PORTUGAL, S.A. - Rua Quinta do Pinheiro, 5 - 2794-003 Carnaxide
NIF: 500043256



Nome: Eylea 40 mg/ml solução injetável num frasco para injetáveis. **Composição:** 1 ml de solução injetável contém 40 mg de aflibercept. **Forma Farmacêutica:** Solução injetável. **Indicações terapêuticas:** Eylea é indicado em adultos para o tratamento da degenerescência macular relacionada com a idade (DMI) neovascular (húmida). **Posologia e modo de administração:** Eylea é apenas para injeção intravítrea. A dose recomendada para Eylea é de 2 mg de aflibercept, equivalente a 50 microlitros. O tratamento com Eylea é iniciado com uma injeção por mês durante três doses consecutivas, seguido de uma injeção a cada dois meses. Não há necessidade de monitorização entre injeções. Após os primeiros 12 meses de tratamento com Eylea, o intervalo entre tratamentos pode ser prolongado com base nos resultados visuais e anatómicos. Neste caso o esquema de monitorização deve ser determinado pelo médico assistente e pode ser mais frequente do que o esquema de injeções. Cada frasco para injetáveis deve ser utilizado apenas para o tratamento de um olho. O frasco para injetáveis contém mais do que a dose recomendada de 2 mg. O volume extraível do frasco para injetáveis (100 microlitros) não é para ser utilizado no total. O excesso de volume deve ser eliminado antes de injetar. Injetar a totalidade do volume poderá resultar em sobredosagem. **Populações especiais:** **Afeção hepática e/ou compromisso renal:** Não foram realizados estudos específicos com Eylea em doentes com afeção hepática e/ou compromisso renal. Os dados disponíveis não sugerem a necessidade de ajustes posológicos com Eylea nestes doentes. **População idosa:** Não são necessárias considerações especiais. **População pediátrica:** A segurança e a eficácia em crianças e adolescentes não foram estabelecidas. **Contraindicações:** Hipersensibilidade à substância ativa aflibercept ou a qualquer um dos excipientes. Infecção ocular ou periocular ativa ou suspeita. Inflamação intraocular ativa grave. **Advertências e precauções especiais de utilização:** Endoftalmite; Aumento da pressão intraocular; Imunogenicidade; Efeitos sistémicos; Doentes com fatores de risco associados ao desenvolvimento de rasgadura do epitélio pigmentado da retina; Doentes com descolamento regmatogénico da retina ou com buracos maculares de fase 3 ou 4; Doentes com descolamento da retina; Nos casos de uma redução na acuidade visual corrigida (BCVA) de ≥ 30 letras em comparação com a última avaliação da acuidade visual, de uma hemorragia subretiniana envolvendo o centro da fóvea, ou, se a dimensão da hemorragia for $\geq 50\%$ da área total da lesão, de uma cirurgia intraocular realizada nos 28 dias anteriores ou planeada para os próximos 28 dias. **Interações medicamentosas:** Não foram realizados estudos de interação. A utilização adjuvante de terapêutica fotodinâmica (TFD) com verteporfina e Eylea não foi estudada, por este motivo o perfil de segurança não está estabelecido. **Efeitos indesejáveis:** Hemorragia conjuntival; Dor ocular; Descolamento da retina; Rasgadura do epitélio pigmentado da retina; Descolamento do epitélio pigmentado da retina; Degenerescência retiniana; Catarata; Catarata nuclear; Catarata subcapsular; Abrasão da córnea; Aumento da pressão intraocular; Visão turva; Edema da córnea; Descolamento do vítreo; Dor no local de injeção; Sensação de corpo estranho nos olhos; Aumento da lacrimação; Edema palpebral; Hemorragia no local de injeção; Hiperemia conjuntival; Hiperemia ocular; Hipersensibilidade; Endoftalmite; Rasgadura da retina; Hemorragia do vítreo; Catarata cortical; Opacidades do cristalino; Deficiência do epitélio da córnea; Erosão da córnea; Irritação no local da injeção; Sensação anormal no olho; Irritação palpebral; Vitrite; Uveíte; Irite; Iridociclite; Flare da câmara anterior; Hipópio; Acontecimentos tromboembólicos arteriais (enfarte do miocárdio não fatal, acidente vascular cerebral não fatal ou morte vascular (incluindo mortes de causa desconhecida)); Potencial imunogenicidade. **Número da A.L.M.:** . Frasco para injetáveis: 5487376. **Data de revisão do texto:** Novembro 2012