

# FramingHam

*on ophthalmology*

Vitreous attachment in age-related macular degeneration, diabetic macular edema, and retinal vein occlusion: a systematic review and metaanalysis

*Retina, 2013 June; 33(6):1099–1108*

Cyclodialysis induced persistent hypotony:  
surgical management with vitrectomy and endotamponade

*Retina, 2013 April 17; Epub ahead of print*

Visual and anatomical outcomes of intravitreal aflibercept  
in eyes with persistent subfoveal fluid despite previous treatments with ranibizumab  
in patients with neovascular age-related macular degeneration

*Retina, 2013 March 30; Epub ahead of print*

Strategy for the management of complex retinal detachments:  
the European Vitreo-Retinal Society Retinal Detachment Study report 2

*Ophthalmology, 2013 April 16; Epub ahead of print*

Pars plana vitrectomy with medium-term postoperative perfluoro-*n*-octane for recurrent  
inferior retinal detachment complicated by advanced proliferative vitreoretinopathy

*Retina, 2013 April; 33(4):791–7*

Two episodes of anaphylaxis following exposure  
to hydroxypropyl methylcellulose during cataract surgery

*Journal of Cataract and Refractive Surgery, 2013 June; 39(6):948–51*

Photodynamic therapy for chronic central serous chorioretinopathy.  
A 4-year follow-up study

*Retina, 2013 February; 33(2):309–15*

*and more...*

**CURRENT TITLES**

Framingham *on atherosclerosis*  
 Framingham *on breast cancer*  
 Framingham *on depression*  
 Framingham *on dermatology*  
 Framingham *on diabetes*  
 Framingham *on gastroenterology*  
 Framingham *on haematological malignancies*  
 Framingham *on hepatitis*  
 Framingham *on hypertension*  
 Framingham *on infectious diseases*  
 Framingham *on lung cancer*  
 Framingham *on neuropathic pain*  
 Framingham *on Parkinson's disease*  
 Framingham *on renal cell carcinoma*  
 Framingham *on thrombosis*  
 Framingham *on urology*  
*and many more...*

**OUR PURPOSE**

The Framingham series of publications is designed to meet clinical specialists' need for a reliable guide to the most important articles appearing in their field.

Each issue presents an authoritative selection from the recently published literature, with the emphasis on evidence-based medicine. Articles are recommended for inclusion by Framingham's editorial office and an advisory board headed by key opinion leaders in the relevant clinical area.

Framingham's team of medical writers prepares original abstracts of these articles, in a structured format that presents the main points at a glance. Our aim is to convey the essence of each article in a concise but readable style.

Issues are published every three to four months.

**ADVISORY BOARD**

Ângela Carneiro, MD PhD\*  
 Hospital São João  
 Porto, Portugal

Angelina Meireles, MD\*  
 Porto Hospital Centre -  
 Hospital Santo António  
 Porto, Portugal

Nuno Gomes, MD\*  
 Hospital of Braga  
 Braga, Portugal

Ricardo Faria, MD\*  
 Hospital São Teotónio  
 Viseu, Portugal

Rufino Silva, MD PhD\*  
 University Hospital of Coimbra  
 Association for Innovation and  
 Biomedical Research on Light  
 and Image (AIBILI)  
 Coimbra, Portugal

Teresa Quintão, MD\*  
 Gama Pinto Ophthalmology  
 Institute  
 Lisbon, Portugal

\*on behalf of the "Retina Study Group (GER)", Portugal

**DISCLAIMER**

The abstracts in this publication are prepared with care to reflect the views expressed by the author or authors of the original source material. These views are not necessarily those of the publisher. While every care is taken to avoid errors, these cannot always be avoided; readers are advised to independently validate any data and recommendations contained herein before acting on this information. The publisher disclaims any responsibility or liability for the accuracy of such information.

**Framingham****Editor**

Neil Carter Abbot

**Medical Writers (this issue)**

Patricia Gosling  
 Jane Grills  
 David Newton

**Art Director**

Jan van Halm

**Layout and Printing**

Van den Berg,  
 Zwijndrecht, the Netherlands

**Publishing Director**

Evelien Enter

**Publisher**

Waldemar H.G. Dobrowolski

**Framingham bv**

Amaliaaan 126 G  
 3743 KJ Baarn  
 The Netherlands  
 framingham@framingham.nl

Framingham *on ophthalmology* is supported by an unrestricted educational grant from  
**Bayer Portugal S.A.**  
 Carnaxide, Portugal

© 2013 Framingham bv

## COMMENTARY PAGE OPHTHALMOLOGY

By *Rufino Silva, MD PhD*

This new 2013 Framingham on Ophthalmology compiles 7 articles with significant relevance to ophthalmologists engaged in medical and surgical retina which can change or modulate our clinical practice.

The first manuscript - Vitreous attachment in age-related macular degeneration, diabetic macular edema, and retinal vein occlusion: a systematic review and metaanalysis, from Jackson TL et al - addresses the role of the vitreous in the clinical course of three of the most frequent retinal pathologies: AMD, DME and RVO. The clinical course of AMD, DME and RVO may be adversely affected by VMA and an attached vitreous. This metaanalysis showed that patients with wet AMD (there was not enough data to determine the prevalence of VMA or PVD in patients with DME and the prevalence of PVD was higher in RVO than in controls) have an increased prevalence of vitreomacular adhesion and a decreased prevalence of posterior vitreous detachment. The role of VMA and the emergence of new therapies for VMT are important issues raised for discussion based on these results.

In the second manuscript - Cyclodialysis induced persistent hypotony: surgical management with vitrectomy and endotamponade Retina, 2013 - Medeiros and col describe a successful surgical treatment of hypotony secondary to cyclodialysis, an important information for the treatment of this rare condition, associated with potential problems and even permanent loss of vision.

The third manuscript - Visual and anatomical outcomes of intravitreal aflibercept in eyes with persistent subfoveal fluid despite previous treatments with ranibizumab in patients with neovascular age-related macular degeneration –a retrospective study - brings new and important information in the era of anti-angiogenesis: Intravitreal aflibercept may improve several visual and anatomical

outcomes in patients with treatment-resistant neovascular AMD.

In the fourth manuscript Adelman RA, for the European Vitreo-Retinal Society(EVRS) Retinal Detachment Study Group, describes the results of a non-randomized, multicentre, retrospective study (data from 176 surgeons in 48 countries on a total of 7678 RRDs) examining which procedures and manoeuvres can be most beneficial for the treatment of specific types of complex RRD, concluding. The findings suggested that vitrectomy is the procedure of choice for patients with retinal detachment when choroidal detachment, hypotony, or a giant tear is present. When PVR was present, tamponade with either gas or silicone oil were appropriate treatment options.

In the fifth manuscript S. Charles and Col. describe the results of Pars plana vitrectomy with medium-term postoperative perfluoro-n-octane for recurrent inferior retinal detachment complicated by advanced proliferative vitreoretinopathy. In spite of potential complications this technique seems to be a viable option for the management of recurrent inferior retinal detachments complicated by grade C PVR.

The seventh manuscript reports a clinical case of an anaphylactic reaction to HPMC, a compound widely used in medical preparations, underscores the importance of carrying out a complete allergen investigation following an anaphylactic reaction, and for surgeons to be aware of potential causes of anaphylaxis, even from substances not normally suspected of being allergenic.

In the last manuscript Silva et al describe the 4 year results (retrospective study) of PDT (standard fluence) for CSC. Besides the significant VA improvement and the resolution of exsudation, the most important result of this study is the finding that there is not retinal atrophy 4 years after treatment.

# VITREOUS ATTACHMENT IN AGE-RELATED MACULAR DEGENERATION, DIABETIC MACULAR EDEMA, AND RETINAL VEIN OCCLUSION: A SYSTEMATIC REVIEW AND METAANALYSIS

*Retina*, 2013 June; 33(6):1099–1108

AUTHORS: JACKSON TL, NICOD E, ANGELIS A, GRIMACCIA F, PREVOST AT, SIMPSON AR, KANAVOS P

CENTRES: GUTHRIE CLINIC, KING'S COLLEGE HOSPITAL; DEPARTMENT OF SOCIAL POLICY, LSE HEALTH; SCHOOL OF ECONOMICS AND POLITICAL SCIENCE; DEPARTMENT OF PRIMARY CARE AND PUBLIC HEALTH SCIENCES; DEPARTMENT OF OPHTHALMOLOGY, KING'S COLLEGE LONDON, LONDON, UK

**BACKGROUND & AIM:** Neovascular (wet) age-related macular degeneration (AMD), diabetic macular oedema (DME) and retinal vein occlusion (RVO) are all associated with and adversely affected by increased levels of vascular endothelial growth factor. Posterior vitreous detachment (PVD) is common in older people and has only minimal obvious clinical consequences, but it may enhance the diffusion of endogenous vascular endothelial growth factor away from the macula, adversely affecting the course of each disease. Also, vitreomacular traction (VMT) occurring in cases of abnormal vitreomacular adhesion (VMA) can cause macular oedema and vision loss. These associations suggest that the clinical course of AMD, DME and RVO may be adversely affected by VMA and an attached vitreous, and the aim of this study was investigate these aspects further.

**STUDY DESIGN:** Systematic review and meta-analysis.

**ENDPOINTS:** Prevalence of VMA and PVD.

**METHOD:** A search of the PubMed MEDLINE database identified 16 eligible studies providing data (of sufficient quality for inclusion in a pooled analysis) on the prevalence of VMA, VMT and PVD in patients with AMD, DME or RVO. In all cases, VMT and VMA were diagnosed using optical coherence tomography. Data were

extracted by two independent reviewers, and mean prevalence data were weighted so that larger studies had a greater impact on the final analysis. Meta-analysis was performed using either fixed or random effect methods, depending on the degree of heterogeneity.

**RESULTS:** The prevalence of VMA was 22.6% in patients with wet AMD, which was significantly higher than that in unaffected control subjects (7.7%; relative risk 2.15, 95% confidence interval 1.34–3.48,  $p=0.002$ ), and also higher, though not significantly, in patients with dry AMD (9.5%; RR 2.54, 95% CI 0.88–7.36,  $p=0.09$ ). The prevalence of complete PVD in patients with wet AMD was 40.6%, which was significantly lower than for controls (55.0%; RR 0.77, 95% CI 0.64–0.93,  $p=0.007$ ) but not for dry AMD (51.0%; RR 0.56, 95% CI 0.27–1.14,  $p=0.11$ ). There was not enough data to determine the prevalence of VMA or PVD in patients with DME, but VMT was recorded in 28.7% of 188 surgical cases. The prevalence of PVD was 30.4% in patients with central RVO and 31.0% in branch RVO, compared with 25.0% in controls, but there was not enough data for meta-analysis.

**CONCLUSION:** Patients with wet AMD have an increased prevalence of vitreomacular adhesion and a decreased prevalence of posterior vitreous detachment.

## CYCLODIALYSIS INDUCED PERSISTENT HYPOTONY: SURGICAL MANAGEMENT WITH VITRECTOMY AND ENDOTAMPONADE

*Retina, 2013 April 17; Epub ahead of print*

AUTHORS: MEDEIROS MD, POSTORINO M, PALLÁS C, SALINAS C, MATEO C, GARCIA-ARUMÍ J, CORCÓSTEGUI B  
CENTRE: INSTITUTO DE MICROCIROLOGIA OCULAR, BARCELONA, SPAIN

**BACKGROUND & AIM:** A cyclodialysis cleft occurs when the meridional ciliary muscle fibres are separated from the scleral spur, often as a result of blunt ocular trauma or during intraocular surgery. Consequently, a new route for drainage of aqueous humour into the suprachoroidal space leads to a fall in intraocular pressure (IOP), which is associated with a range of potential problems and may even cause permanent loss of vision. A number of therapeutic techniques have been described for use in cases where conservative management is not effective, but these have not been evaluated formally. This article describes the therapeutic approach taken for 6 patients with cyclodialysis and hypotony.

**ARTICLE TYPE:** Case reports.

**FINDINGS:** Six patients with traumatic cyclodialysis and hypotony maculopathy affecting one eye were treated with different approaches at a single centre. Cyclodialysis cleft occurred after blunt trauma in 4 patients, anterior chamber angle-supported intraocular lens implantation in one patient, and complicated cataract surgery in another. One patient underwent a microincisional vitrectomy with injection of silicone oil into the posterior segment, and achieved an improvement in visual acuity from 20/100 to 20/63 at one month, and an increase in IOP from 2 to 10 mmHg. A second patient

received combined penetrating keratoplasty and vitreoretinal surgery followed by silicone oil internal retinal tamponade. One month after the procedure, visual acuity had improved from counting fingers to 20/400, while IOP had increased from 2 to 6 mmHg, and both parameters continued to improve over the next 10 months.

Two other patients underwent microincisional vitrectomy, in both cases following a poor response to conservative therapy (including topical steroids and atropine). In one patient, IOP increased from 2 to 18 mmHg after 3 months, and visual acuity improved from counting fingers at 0.5 m to 20/400. In the other, IOP rose from 6 to 12 mmHg after 15 days, while visual acuity improved from 20/50 to 20/40 after 4 months. Two further patients received microincisional 23-gauge pars plana vitrectomy and internal limiting membrane peeling, and a three-port vitrectomy with subretinal injection of recombinant tissue plasminogen activator and 20% SF<sub>6</sub> tamponade, respectively. IOP and visual acuity improved in these 2 cases also. The ciliary body was completely reattached in all patients.

**CONCLUSION:** Pars plana vitrectomy followed by silicone oil or gas-assisted endotamponade can be an effective approach for stabilizing eyes with cyclodialysis and macular hypotony.

# VISUAL AND ANATOMICAL OUTCOMES OF INTRAVITREAL AFLIBERCEPT IN EYES WITH PERSISTENT SUBFOVEAL FLUID DESPITE PREVIOUS TREATMENTS WITH RANIBIZUMAB IN PATIENTS WITH NEOVASCULAR AGE-RELATED MACULAR DEGENERATION

*Retina, 2013 March 30; Epub ahead of print*

AUTHORS: KUMAR N, MARSIGLIA M, MREJEN S, FUNG AT, SLAKTER J, SORENSON J, FREUND KB

CENTRES: VITREOUS, RETINA, MACULA, CONSULTANTS OF NEW YORK AND THE LUESTER T. MERTZ RETINAL RESEARCH CENTER, MANHATTAN EYE, EAR, AND THROAT INSTITUTE; DEPARTMENT OF OPHTHALMOLOGY, NEW YORK UNIVERSITY SCHOOL OF MEDICINE; DEPARTMENT OF OPHTHALMOLOGY, COLUMBIA UNIVERSITY, NEW YORK, NEW YORK, USA; MOORFIELDS EYE HOSPITAL, LONDON, UK

**BACKGROUND & AIM:** While anti-vascular endothelial growth factor (VEGF) agents, such as ranibizumab, can be effective for the treatment of neovascular age-related macular degeneration (AMD), a significant proportion of patients still have persistent fluid after therapy. Increasing the dose or frequency of existing treatments has not proved effective or practical for overcoming this, but finding a drug with a higher VEGF binding affinity is another potential strategy for improving outcomes. Aflibercept is an intravitreal VEGF agonist which binds to VEGF-A, VEGF-B and placental growth factor. The aim of this study was to investigate the efficacy of this treatment in patients with treatment-resistant neovascular AMD.

**STUDY DESIGN:** Retrospective cohort study.

**ENDPOINTS:** Visual acuity, central foveal thickness, and pigment epithelial detachment (PED) height and diameter.

**METHOD:** The analysis was performed on data from 34 eyes of 33 patients (mean age

79 years) with AMD and persistent subretinal and/or intraretinal fluid despite treatment with at least 3 intravitreal injections of ranibizumab 0.5 mg. All were switched to treatment with intravitreal aflibercept injections for at least 6 months, and the time between the last ranibizumab and the first aflibercept dose was no longer than 42 days. Visual acuity was measured using a standard assessment protocol, and optical coherence tomography was performed to measure central foveal thickness, foveal PED height, subretinal fluid and retinal thickness. The maximum height and diameter of a PED was also measured.

**RESULTS:** After 6 months of treatment with aflibercept, the mean visual acuity in the cohort improved from 20/75 to 20/60 ( $p=0.004$ ), while the logarithm of the minimum angle of resolution decreased from  $0.57\pm 0.36$  to  $0.47\pm 0.32$  (Table). In addition, the central foveal thickness improved ( $p<0.001$ ), the maximum PED height decreased ( $p<0.001$ ), and the PED diameter decreased ( $p=0.04$ ), as shown in the Table. In addition, there was a significant reduction in the sub-retinal pigment epithelium space and the subretinal fluid, but not in the retinal thickness.

**CONCLUSION:** Intravitreal aflibercept improved several visual and anatomical outcomes in patients with treatment-resistant neovascular AMD.

Visual and anatomical results

Parameter	Baseline (mean±SD)	Follow-up at 6 months (mean±SD)	p-value
Visual acuity (logMAR)	0.57±0.36	0.47±0.32	0.004
Central foveal thickness (µm)	416±217	348±171	<0.001
Subfoveal distance between Bruch membrane and retinal pigment epithelium (µm)	187±158	149±125	0.002
Subfoveal PED height (µm)	260±162	215±142	<0.001
Subfoveal PED diameter (µm)	3265±1622	2949±1634	0.04

# STRATEGY FOR THE MANAGEMENT OF COMPLEX RETINAL DETACHMENTS: THE EUROPEAN VITREO-RETINAL SOCIETY RETINAL DETACHMENT STUDY REPORT 2

*Ophthalmology*, 2013 April 16; Epub ahead of print

AUTHORS: ADELMAN RA, PARNES AJ, SIPPERLEY JO, DUCOURNAU D; FOR THE EUROPEAN VITREO-RETINAL SOCIETY (EVRS) RETINAL DETACHMENT STUDY GROUP

CENTRES: DEPARTMENT OF OPHTHALMOLOGY & VISUAL SCIENCE, YALE UNIVERSITY SCHOOL OF MEDICINE, NEW HAVEN, CONNECTICUT; BARNET DULANEY PERKINS EYE CENTER, PHOENIX, ARIZONA, USA; EVRS, NANTES, FRANCE

**BACKGROUND & AIM:** No global standard of care has been defined for the treatment of complex rhegmatogenous retinal detachments (RRDs). The management of RRD with complicating factors, such as proliferative vitreoretinopathy (PVR), giant retinal tear, choroidal detachment or macular hole, is typically based on surgeon preference and experience. An evidence-based approach is needed to provide optimal treatment in these cases, and the aim of this study was to use data from a large number of RRD cases to examine which procedures and manoeuvres can be most beneficial for the treatment of specific types of complex RRD.

**STUDY DESIGN:** Non-randomized, multi-centre, retrospective study.

**ENDPOINT:** Failure of retinal detachment repair.

**METHOD:** Information was received from 176 surgeons in 48 countries on a total of 7678 RRDs which had undergone operative procedures. Treatment failure was categorized as one of 3 levels: the true failure rate representing eyes with detached retina judged to be inoperable by study conclusion (level 1); the percentage of eyes that had silicone oil remaining in the eye at study conclusion (level 2); and the percentage of eyes that had a recurrence of the detachment or

a complication after the initial procedure that required additional surgery (level 3). Univariate and bivariate analyses were carried out to identify variables associated with the rate of failure.

**RESULTS:** In cases of grade B PVR ( $n=917$ ), the level 1 failure rate was higher in patients treated with scleral buckle alone than in patients who had undergone a vitrectomy ( $p=0.0017$ ). In grade C-1 PVR ( $n=637$ ), vitrectomy with a supplemental buckle showed a significantly increased failure rate compared with vitrectomy alone ( $p=0.007$ ). The level 1 failure rate of tamponade with gas versus tamponade with silicone oil did not differ significantly in grade B or C-1 PVR. In cases of choroidal detachment or hypotony, vitrectomy resulted in a significantly lower failure rate compared with scleral buckle alone ( $p=0.0015$ ). Treatment with vitrectomy also resulted in a significantly lower rate of failure in patients with large or giant retinal tears, compared with treatment with scleral buckle ( $p=7\times 10^{-8}$ ).

**CONCLUSIONS:** The findings of this large retrospective study suggest that vitrectomy is the procedure of choice for patients with retinal detachment when choroidal detachment, hypotony, or a giant tear is present. In PVR, tamponade with either gas or silicone oil were appropriate treatment options.

# PARS PLANA VITRECTOMY WITH MEDIUM-TERM POSTOPERATIVE PERFLUORO-N-OCTANE FOR RECURRENT INFERIOR RETINAL DETACHMENT COMPLICATED BY ADVANCED PROLIFERATIVE VITREORETINOPATHY

*Retina*, 2013 April; 33(4):791–7

AUTHORS: SIGLER EJ, RANDOLPH JC, CALZADA JI, CHARLES S  
CENTRE: CHARLES RETINA INSTITUTE, MEMPHIS, TENNESSEE, USA

**BACKGROUND & AIM:** Proliferative vitreoretinopathy (PVR) is a frequent cause of surgical failure and recurrent retinal detachment, despite rapid advances in microsurgical techniques and treatments. Perfluoro-*n*-octane (PFO) has become a useful tool in recent years as an adjunct to pars plana vitrectomy (PPV) in the intraoperative management of retinal detachment. Several reports have suggested that PFO may be left in the vitreous cavity postoperatively for short durations without adverse effects, and may be useful for inferior retinal tamponade. The aim of this study was to examine outcomes in a series of patients with recurrent inferior retinal detachment complicated by PVR who were treated with pars plana vitrectomy and postoperative PFO.

**STUDY DESIGN:** Prospective, interventional case series.

**ENDPOINTS:** Visual acuity, and anatomical reattachment rate at final follow-up.

**METHOD:** The study included 44 eyes of 44 consecutive patients presenting with recurrent inferior retinal detachment, grade C PVR, and primary retinal break limited to the inferior 6 clock hours of the posterior segment. Patients were initially treated with 25-gauge PPV, with the second-stage procedure carried out 2–3 weeks after the initial PPV and before PFO removal.

**RESULTS:** During a mean follow-up of 30.7 months, successful reattachment was achieved in 38 of the 44 eyes treated (86%). No significant difference was observed in reattachment rates between eyes with and without previous scleral buckle. Of the 6 eyes in which redetachment occurred, 4 were due to recurrent inferior PVR, and 2 were due to a new superior break without PVR. Complications observed in the initial and secondary postoperative period included inflammation (32% of patients), intraocular pressure elevation (36%) and cataract progression requiring surgery. Cataract extraction was required in 8 of 19 patients (42%) of initially phakic eyes. The presence of previous scleral buckle was not related to final anatomical ( $p=0.27$ ) or visual acuity outcome ( $p=0.41$ ). Macula-off status ( $p=0.02$ ) and persistent intraocular pressure elevation ( $p=0.02$ ) were associated with worse visual outcome.

**CONCLUSIONS:** In spite of potential complications, such as inflammation and elevated intraocular pressure, intermediate-duration postoperative PFO in patients with advanced proliferative vitreoretinopathy and inferior retinal redetachment appeared to be a viable option for the management of recurrent inferior retinal detachments complicated by grade C PVR.



## TWO EPISODES OF ANAPHYLAXIS FOLLOWING EXPOSURE TO HYDROXYPROPYL METHYLCELLULOSE DURING CATARACT SURGERY

*Journal of Cataract and Refractive Surgery*, 2013 June; 39(6):948–51

AUTHORS: MUNK SJ, HEEGAARD S, MOSBECH H, GARVEY LH

CENTRES: EYE PATHOLOGY INSTITUTE, DEPARTMENT OF NEUROSCIENCE AND PHARMACOLOGY, UNIVERSITY OF COPENHAGEN; DEPARTMENT OF OPHTHALMOLOGY, GLOSTRUP HOSPITAL; DANISH ANAESTHESIA ALLERGY CENTRE, ALLERGY CLINIC, COPENHAGEN UNIVERSITY HOSPITAL, GENTOFTE, COPENHAGEN, DENMARK

**BACKGROUND & AIM:** There have been occasional reports of anaphylaxis after cataract surgery. As numerous drugs are typically administered during and after the procedure, however, it is difficult to establish the exact cause of the anaphylaxis at the time. Subsequent allergen investigation is necessary to find the causative agent and prevent exposure in future. This study describes a patient who underwent otherwise uneventful cataract surgery on the left eye, followed by the right eye 2 years later, and who experienced immediate and severe anaphylaxis on both occasions. Skin prick tests were carried out following the second occurrence of anaphylaxis to determine which substance was the causative agent.

**STUDY DESIGN:** Case report.

**ENDPOINTS:** Skin prick test results.

**METHOD:** A 71-year-old man with no relevant medical history or previous history of allergic reactions underwent cataract surgery in October 2009 on his left eye. Following the operation, the patient experienced severe palmar itching, dizziness, abdominal pain, nausea, vomiting, and a swelling in his throat. The patient collapsed on the floor, semiconscious, and was subsequently admitted to hospital where he was successfully treated with inhalation of adrenaline, antihistamine and steroids. Two

years later, cataract surgery was planned for the right eye by the same surgeon. Suspecting that the antibiotics used during surgery were the cause of the former anaphylactic reaction, the surgeon changed antibiotics but kept to the same procedure. The patient experienced another anaphylactic response on the occasion of the second surgery. All medications used during both cataract operations, including local anaesthesia agents, anti-inflammatory drugs, lubricants and fillers were tested on the patient for an allergic reaction.

**RESULTS:** Skin prick tests were positive for Ocucoat, which is formulated from a hydroxypropyl methylcellulose (HPMC) 2% and Xylocaine gel. Subsequent skin prick tests for HPMC and methylcellulose 2% were also strongly positive. However, a prick test with Diprosan (containing carboxymethylcellulose) was inconclusive, while a test with Instillagel (containing hydroxyl ethylcellulose) was negative.

**CONCLUSIONS:** This case report of an anaphylactic reaction to HPMC, a compound widely used in medical preparations, underscores the importance of carrying out a complete allergen investigation following an anaphylactic reaction, and for surgeons to be aware of potential causes of anaphylaxis, even from substances not normally suspected of being allergenic.

## PHOTODYNAMIC THERAPY FOR CHRONIC CENTRAL SEROUS CHORIORETINOPATHY. A 4-YEAR FOLLOW-UP STUDY

*Retina*, 2013 February; 33(2):309–15

AUTHORS: SILVA RM, RUIZ-MORENO JM, GOMEZ-ULLA F, MONTERO JA, GREGÓRIO T, CACHULO ML, PIRES IA, CUNHA-VAZ JG, MURTA JN

CENTRE FOR CORRESPONDENCE: DEPARTMENT OF OPHTHALMOLOGY, COIMBRA UNIVERSITY HOSPITAL CENTER, COIMBRA, PORTUGAL

**BACKGROUND & AIM:** Standard photodynamic therapy (PDT) with verteporfin is recommended for patients with central serous chorioretinopathy (CSC) whose symptoms have not resolved within 3 months. The aim of this study was to evaluate the long-term efficacy and safety of standard PDT in these patients.

**STUDY DESIGN:** Retrospective case series.

**ENDPOINTS:** Best-corrected visual acuity (BCVA), neural retina thickness, and resolution of subretinal fluid.

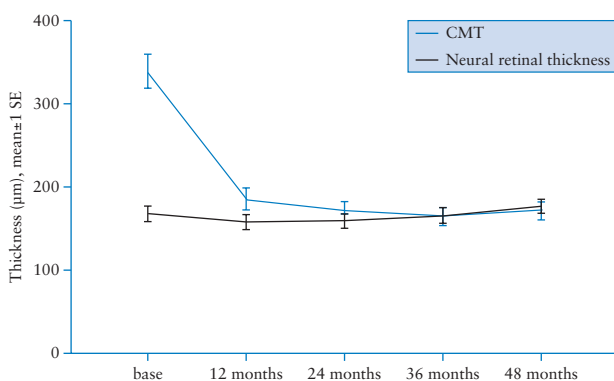
**METHOD:** Patients with chronic CSC were treated with standard PDT with verteporfin, and followed up for at least 4 years. Patients were evaluated quarterly during the first year, every 6 months in the second year, and annually thereafter. At each visit,

including baseline, BCVA was determined with Early Treatment Diabetic Retinopathy Study charts, and mandatory optical coherence tomography (OCT) was performed to ascertain subretinal fluid levels, evaluate structural changes and measure central macular thickness (CMT). Retinal thickness was measured manually from OCT findings.

**RESULTS:** The study included 46 eyes from 42 patients (mean age 49.2 years; 38 men and 4 women), and mean duration of follow-up was 56.8 months. At baseline, subretinal fluid was observed in all study eyes, and 10 eyes (21.7%) had intraretinal diffuse or cystoid fluid. BCVA improved significantly from baseline to 4-year follow-up (58.8 versus 66.9 letters;  $p < 0.001$ ). At 4 years, complete resolution of subretinal fluid was observed in 93.4% of the eyes, and complete resolution of intraretinal fluid occurred in the 10 eyes affected. Mean CMT reduced from 316  $\mu\text{m}$  at baseline to 169.7  $\mu\text{m}$  at 48 months ( $p < 0.001$ ), while neural retina thickness, i.e. CMT excluding the subretinal fluid, was stable during the follow-up period (Figure). No systemic or ocular side effects related to treatment were reported.

**CONCLUSIONS:** In patients with chronic central serous chorioretinopathy, PDT with verteporfin was associated with a significant long-term clinical improvement in visual acuity and a resolution of subretinal fluid without additional retinal atrophy or adverse local or systemic side-effects.

CMT (including intraretinal and subretinal fluids) and neural retina thickness after PDT with verteporfin



## RISK OF ELEVATED INTRAOCULAR PRESSURE AND GLAUCOMA IN PATIENTS WITH UVEITIS: RESULTS OF THE MULTICENTER UVEITIS STEROID TREATMENT TRIAL

*Ophthalmology*, 2013 April 16; Epub ahead of print

AUTHORS: FRIEDMAN DS, HOLBROOK JT, ANSARI H, ALEXANDER J, BURKE A, REED SB, KATZ J, THORNE JE, LIGHTMAN SL, KEMPEN JH; FOR THE MUST RESEARCH GROUP  
CENTRE FOR CORRESPONDENCE: DEPARTMENT OF OPHTHALMOLOGY, MOUNT SINAI SCHOOL OF MEDICINE, NEW YORK, NEW YORK, USA

**BACKGROUND & AIM:** Intraocular pressure (IOP) is often increased in patients with uveitis, probably as a result of chronic inflammation, and may be further raised as a consequence of corticosteroid treatment. The Multicenter Uveitis Steroid Treatment (MUST) trial found that visual acuity outcomes were similar in patients treated with intravitreal fluocinolone acetonide implants and in those who received systemic therapy, but the implants were associated with more ocular complications including glaucoma. The aim of the current analysis was to determine the incidence of raised IOP and glaucomatous optic nerve damage in participants in the TRUST trial.

**STUDY DESIGN:** Randomized partially-masked trial.

**ENDPOINTS:** IOP elevation and glaucomatous optic nerve damage.

**METHOD:** The study included 129 patients (245 eyes with uveitis), aged at least 13 years, with non-infectious intermediate,

posterior, or panuveitis in one or both eyes, for which systemic corticosteroids were indicated. None had uncontrolled glaucoma or advanced glaucoma damage. They were randomized to receive either fluocinolone acetonide implants or systemic therapy (which was typically prednisone plus immunosuppressive drugs when indicated), and were subsequently followed up for at least 2 years. IOP was measured using Goldmann applanation tonometry, and stereoscopic optic nerve photos were also taken.

**RESULTS:** An elevation in IOP of at least 10 mmHg was significantly more likely in patients who received an implant than in those who received systemic therapy (65 versus 24%, respectively;  $p < 0.001$ ), while those assigned to an implant were also more likely to require IOP-lowering therapy (69 versus 26%, respectively;  $p < 0.001$ ). Furthermore, the development of glaucomatous optic nerve damage was significantly more common in patients assigned to implants than in those on systemic therapy (23 versus 6%, respectively;  $p < 0.001$ ). Black race, use of IOP-lowering medications and uveitis activity at baseline were also associated with the development of glaucoma (Table).

**CONCLUSIONS:** Implant therapy for uveitis was associated with an increased risk of IOP elevation and glaucoma, compared with systemic therapy, indicating that frequent IOP monitoring is required for these individuals.

Association of baseline characteristics with glaucoma diagnosis

Characteristic	Adjusted relative risk (95% confidence interval)	p-value
Treatment; implant versus systemic	4.09 (1.80–9.28)	<0.001
Age; ≥50 versus <50	0.65 (0.34–1.27)	0.21
Race; black versus other	1.91 (1.01–3.62)	0.05
Sex; male versus female	0.88 (0.40–1.92)	0.74
Glaucoma medications; yes versus no	2.24 (1.20–4.18)	0.01
Uveitis activity; active versus not active	3.22 (1.11–9.29)	0.03

## THE INFLUENCE OF BACKGROUND DIABETIC RETINOPATHY IN THE SECOND EYE ON RATES OF PROGRESSION OF DIABETIC RETINOPATHY BETWEEN 2005 AND 2010

*Acta Ophthalmologica*, 2013 April 1; Epub ahead of print

AUTHORS: SCANLON PH, STRATTON IM, HISTED M, CHAVE SJ, ALDINGTON SJ

CENTRES: GLOUCESTERSHIRE DIABETIC RETINOPATHY RESEARCH GROUP, CHELTENHAM GENERAL HOSPITAL, CHELTENHAM; NHS DIABETIC EYE SCREENING PROGRAMME, GLOUCESTER, UK

**BACKGROUND & AIM:** The UK National Health Service Diabetic Eye Screening Programme currently recommends annual digital photographic screening for all individuals over 12 years of age with diabetes. When patients have evidence of sight-threatening diabetic retinopathy based on referable diabetic retinopathy (RDR) criteria they are referred to their local NHS hospital eye service for continued management. Data from this screening programme was used to investigate the risk of progression of diabetic retinopathy in diabetic patients with no diabetic retinopathy or with mild background retinopathy in one or both eyes.

**STUDY DESIGN:** Retrospective database study.

**ENDPOINT:** Progression to clinically significant diabetic retinopathy.

**METHOD:** Diabetic patients for whom digital retinal photographs were available from at least 2 screening assessments between 2005 and 2010 were included if their classification at first screening was no (R0) or mild background diabetic retinopathy in one (R1a) or both eyes (R1b). Patients were followed up until referable retinopathy was detected or no further screening images were available. The RDR criteria were maculopathy, preproliferative or proliferative retinopathy. Times from baseline screening

to detection of RDR criteria were analysed using survival models.

**RESULTS:** Data from 19,044 patients were reviewed, of whom 56% were men. The median patient age at first screening was 66 years. The median time from first screening to rescreening was 13.5 months and the median follow-up duration was 41 months. A total of 8.3% of patients classed as R1a and 28.2% of those classed R1b progressed to any RDR. Compared with patients without diabetic retinopathy, the hazard ratio for progression to RDR was 2.9 (95% confidence interval 2.5–3.3) in patients with R1a and 11.3 (95% CI 10.0–12.8) in patients with R1b. With regard to specific RDR criteria, 7.1% of patients with R1a progressed to maculopathy (HR 2.7, 95% CI 2.3–3.1) compared with 21.8% of patients with R1b (HR 9.1, 95% CI 7.9–10.4). By contrast, 0.11% of patients with R1a progressed to proliferative retinopathy (HR 1.6, 95% CI 0.5–5.0) compared with 1.07% of those with R1b (HR 15.0, 95% CI 7.1–31.5).

**CONCLUSIONS:** The risk of progression to sight-threatening diabetic retinopathy appears to be significantly higher for patients with background diabetic retinopathy in both eyes than for patients with background retinopathy in one eye only, or with no retinopathy in either eye.

## MACULAR EDEMA AFTER CATARACT SURGERY IN EYES WITHOUT PREOPERATIVE CENTRAL-INVOLVED DIABETIC MACULAR EDEMA

*JAMA Ophthalmology*, 2013 April 18; Epub ahead of print

AUTHORS: DIABETIC RETINOPATHY CLINICAL RESEARCH NETWORK

CENTRE FOR CORRESPONDENCE: JAEB CENTER FOR HEALTH RESEARCH, TAMPA, FLORIDA, USA

**BACKGROUND & AIM:** Studies on diabetes patients undergoing cataract removal have suggested that cataract surgery is a risk factor for the incidence of macular oedema (ME) or a worsening of diabetic retinopathy. Other evidence has indicated, however, that pre-existing diabetic macular oedema (DME) is not needed for ME to occur postoperatively. The aim of this study was to estimate the incidence of central-involved DME in eyes with diabetic retinopathy, but without definite pre-existing central-involved DME, after cataract surgery.

**STUDY DESIGN:** Prospective observational study.

**ENDPOINT:** Incidence of central-involved ME 16 weeks after cataract surgery.

**METHOD:** The study involved 293 eyes from patients with diabetes mellitus and diabetic retinopathy; the mean patient age was 65 years. Eligible eyes had no definite central

subfield thickening evident on optical coherence tomography (OCT) imaging at the preoperative baseline assessment. Patients underwent cataract removal surgery within 28 days of enrolment. OCT was also carried out at a postoperative assessment 16 weeks after surgery. Patients who received non-topical treatment for ME before the 16-week assessment and met either of the OCT criteria for ME at the time of treatment were classed as having central-involved DME.

**RESULTS:** Complete OCT data was available for 261 eyes. Median baseline visual acuity letter score was 69 letters (Snellen equivalent 20/40). At baseline, 128 (44%) of eyes had a history of treatment for DME. None of the 17 eyes without DME at baseline developed central-involved ME at 16 weeks. In eyes with the possibility of DME at baseline, 10 of the 97 eyes (10%) without central-involved DME and 18 of the 147 eyes (12%) with possible central-involved DME had developed central-involved ME at 16 weeks. A history of prior treatment for DME was significantly associated with the postoperative development of central-involved ME ( $p < 0.001$ ; Table).

**CONCLUSION:** In patients with diabetic retinopathy but no definite central-involved DME, the existence of non-centrally involved DME immediately before cataract surgery or a history of DME treatment appear to increase the risk of central-involved ME after cataract removal.

Baseline factors' association with development or progression of central-involved or non-central-involved ME at 16 weeks

Parameter	Central-involved ME	Non-central-involved ME
	<i>p</i> -value	<i>p</i> -value
Visual acuity at baseline	0.06	0.11
Any history of DME treatment	<0.001	<0.001
History of panretinal photocoagulation	0.50	0.31
Diabetic retinopathy severity	0.06	0.08
Glycated haemoglobin level	0.83	>0.99
Age ≥65	0.18	0.28
Female sex	0.44	>0.99
Diabetes mellitus type	0.27	0.13

## EFFECTS OF GRAFT THICKNESS AND ASYMMETRY ON VISUAL GAIN AND ABERRATIONS AFTER DESCemet STRIPPING AUTOMATED ENDOTHELIAL KERATOPLASTY

*JAMA Ophthalmology, 2013 April 11; Epub ahead of print*

AUTHORS: DICKMAN MM, CHENG YY, BERENDSCHOT TT, VAN DEN BIGGELAAR FJ, NUIJTS RM

CENTRES: UNIVERSITY EYE CLINIC MAASTRICHT, MAASTRICHT UNIVERSITY MEDICAL CENTER, MAASTRICHT, THE NETHERLANDS

**BACKGROUND & AIMS:** Descemet stripping automated endothelial keratoplasty (DSAEK) has become the standard corneal transplant technique, but post-graft visual acuity is often suboptimal. Recent evidence suggests that posterior corneal (PC) higher-order aberrations (HOAs) can reduce optical quality after DSAEK, and the aims of this study were to evaluate the relationship(s) between central graft thickness and visual gain after DSAEK, and the relationships between graft thickness, asymmetry of the PC surface, and post-DSAEK HOAs.

**STUDY DESIGN:** Retrospective analysis of an interventional case series.

**ENDPOINTS:** Visual gain, graft thickness, graft asymmetry and PC HOAs

**METHOD:** The study included 79 eyes from 71 patients with corneal endothelial dysfunction. All the study eyes underwent a DSAEK procedure; all DSAEK procedures were carried out by the same surgeon. Visual gain was defined as the difference

between preoperative and 6-month postoperative best-corrected visual acuity (BCVA) expressed in logMAR equivalents. Central graft thickness was measured 6 months postoperatively using anterior-segment optical coherence tomography. Corneal topography and HOAs were measured using a commercially available imaging system.

**RESULTS:** After DSAEK, mean BCVA improved from 0.63 logMAR equivalents preoperatively to 0.25 logMAR equivalents postoperatively, and 67% of all eyes achieved a vision of 20/40 or better (Table). The mean graft thickness measured 6 months postoperatively was 97  $\mu$ m (range 39–145). Visual gain was significantly negatively correlated with graft thickness ( $p=0.02$ ), after excluding patients with vision-limiting co-morbidities. This correlation was strongest in patients who had pseudophakic bullous keratopathy ( $p=0.01$ ). There was a significant positive correlation between PC asymmetry and central graft thickness in the 4-mm and 6-mm zones, which in turn correlated with the number of PC HOAs (with the exception of spherical PC HOAs).

**CONCLUSIONS:** Thinner corneal grafts were associated with greater gains in visual acuity after DSAEK in patients without concurrent vision-limiting conditions. Thicker grafts were associated with greater asymmetry of the PC surface and therefore with more PC HOAs.

Comparison of preoperative and postoperative measurements

Variable	Preoperative	Postoperative	<i>p</i> -value
BCVA, logMAR equivalent; mean (SD)	0.63 (0.50)	0.25 (0.20)	<0.001
Visual acuity, <i>n</i> (%) of eyes			
20/40	28 (35)	53 (67)	<0.001
20/25	0	18 (23)	<0.001
Refractive astigmatism, D; mean (SD)	-1.3 (1.3)	-1.7 (0.9)	0.08
Topographic astigmatism, D; mean (SD)	2.1 (1.7)	1.78 (1.3)	0.14
Spherical equivalent, D; mean (SD)	-0.4 (1.2)	0.1 (1.4)	0.006

... ..





## NOVO tratamento para a DMI<sup>a</sup> exsudativa UMA ADMINISTRAÇÃO A CADA 2 MESES<sup>b</sup> A VIDA PARA ALÉM DAS LETRAS



EYLEA<sup>®</sup> melhora e mantém a visão com uma administração a cada 2 meses<sup>b</sup>, sem necessidade de monitorização entre injeções<sup>1,2</sup>

Os estudos VIEW demonstraram que EYLEA<sup>®</sup> é um tratamento eficaz para a DMI<sup>a</sup> exsudativa, com o potencial de redução do risco associado às injeções intravítreas mensais e ao “peso” da monitorização mensal<sup>2</sup>

<sup>a</sup> DMI - Degenerescência Macular relacionada com a Idade neovascular (húmida)

<sup>b</sup> Após uma injeção por mês durante 3 doses consecutivas

**Referências:** 1. Resumo das Características do Medicamento EYLEA<sup>®</sup>. 2. Heier JS, et al. Intravitreal Aflibercept (VEGF Trap-Eye) in Wet Age-Related Macular Degeneration. *Ophthalmology* 2012; 119: 2537-2548

Medicamento sujeito a receita médica restrita a certos meios especializados.

Para mais informações deverá contactar o titular de AIM  
BAYER PORTUGAL, S.A. - Rua Quinta do Pinheiro, 5 - 2794-003 Carnaxide  
NIF: 500043256



**Nome:** Eylea 40 mg/ml solução injetável num frasco para injetáveis. **Composição:** 1 ml de solução injetável contém 40 mg de aflibercept. **Forma Farmacêutica:** Solução injetável. **Indicações terapêuticas:** Eylea é indicado em adultos para o tratamento da degenerescência macular relacionada com a idade (DMI) neovascular (húmida). **Posologia e modo de administração:** Eylea é apenas para injeção intravítrea. A dose recomendada para Eylea é de 2 mg de aflibercept, equivalente a 50 microlitros. O tratamento com Eylea é iniciado com uma injeção por mês durante três doses consecutivas, seguido de uma injeção a cada dois meses. Não há necessidade de monitorização entre injeções. Após os primeiros 12 meses de tratamento com Eylea, o intervalo entre tratamentos pode ser prolongado com base nos resultados visuais e anatómicos. Neste caso o esquema de monitorização deve ser determinado pelo médico assistente e pode ser mais frequente do que o esquema de injeções. Cada frasco para injetáveis deve ser utilizado apenas para o tratamento de um olho. O frasco para injetáveis contém mais do que a dose recomendada de 2 mg. O volume extraível do frasco para injetáveis (100 microlitros) não é para ser utilizado no total. O excesso de volume deve ser eliminado antes de injetar. Injetar a totalidade do volume poderá resultar em sobredosagem. **Populações especiais:** **Afeção hepática e/ou compromisso renal:** Não foram realizados estudos específicos com Eylea em doentes com afeção hepática e/ou compromisso renal. Os dados disponíveis não sugerem a necessidade de ajustes posológicos com Eylea nestes doentes. **População idosa:** Não são necessárias considerações especiais. **População pediátrica:** A segurança e a eficácia em crianças e adolescentes não foram estabelecidas. **Contraindicações:** Hipersensibilidade à substância ativa aflibercept ou a qualquer um dos excipientes. Infecção ocular ou periocular ativa ou suspeita. Inflamação intraocular ativa grave. **Advertências e precauções especiais de utilização:** Endoftalmite; Aumento da pressão intraocular; Imunogenicidade; Efeitos sistémicos; Doentes com fatores de risco associados ao desenvolvimento de rasgadura do epitélio pigmentado da retina; Doentes com descolamento regmatogénico da retina ou com buracos maculares de fase 3 ou 4; Doentes com descolamento da retina; Nos casos de uma redução na acuidade visual corrigida (BCVA) de  $\geq 30$  letras em comparação com a última avaliação da acuidade visual, de uma hemorragia subretiniana envolvendo o centro da fóvea, ou, se a dimensão da hemorragia for  $\geq 50\%$  da área total da lesão, de uma cirurgia intraocular realizada nos 28 dias anteriores ou planeada para os próximos 28 dias. **Interações medicamentosas:** Não foram realizados estudos de interação. A utilização adjuvante de terapêutica fotodinâmica (TFD) com verteporfina e Eylea não foi estudada, por este motivo o perfil de segurança não está estabelecido. **Efeitos indesejáveis:** Hemorragia conjuntival; Dor ocular; Descolamento da retina; Rasgadura do epitélio pigmentado da retina; Descolamento do epitélio pigmentado da retina; Degenerescência retiniana; Catarata; Catarata nuclear; Catarata subcapsular; Abrasão da córnea; Aumento da pressão intraocular; Visão turva; Edema da córnea; Descolamento do vítreo; Dor no local de injeção; Sensação de corpo estranho nos olhos; Aumento da lacrimação; Edema palpebral; Hemorragia no local de injeção; Hiperemia conjuntival; Hiperemia ocular; Hipersensibilidade; Endoftalmite; Rasgadura da retina; Hemorragia do vítreo; Catarata cortical; Opacidades do cristalino; Deficiência do epitélio da córnea; Erosão da córnea; Irritação no local da injeção; Sensação anormal no olho; Irritação palpebral; Vitrite; Uveíte; Irite; Iridociclite; Flare da câmara anterior; Hipópio; Acontecimentos tromboembólicos arteriais (enfarte do miocárdio não fatal, acidente vascular cerebral não fatal ou morte vascular (incluindo mortes de causa desconhecida)); Potencial imunogenicidade. **Número da A.L.M.:** . Frasco para injetáveis: 5487376. **Data de revisão do texto:** Novembro 2012